

2.2.8 Infectious Salmon Anemia

W.R. Keleher, D. A. Bouchard, and P. L. Merrill

Micro Technologies, Inc.
41 Main Street
Richmond, ME 04357
207/737-2637
microtech@wiscassett.net
dbouchard@microtechnologies.biz

A. Name of Disease and Etiological Agent

Infectious salmon anemia (ISA) is caused by infectious salmon anemia virus (ISAV). The virus is a member of the orthomyxoviridae family. Synonyms include: hemorrhagic kidney syndrome (HKS).

B. Known Geographical Range and Host Species of the Disease

1. Geographical Range

Infectious salmon anemia has been found in Norway, the Faroe Islands, and the United Kingdom (Scotland and Shetland Islands). In North America, the disease has been restricted to the east coast, with cases seen in Canada (New Brunswick) and in the United States (Maine). The virus has also been detected in Nova Scotia, Canada.

2. Host Species

ISA has been noted in only one species of salmonids: Atlantic salmon *Salmo salar*. Sea-run brown trout *Salmo trutta*, rainbow trout *Oncorhynchus mykiss*, and Atlantic herring *Clupea harengus* are potential asymptomatic carriers of the virus.

C. Epizootiology

While age does not appear to be a factor of ISA susceptibility, epizootics have almost exclusively occurred during saltwater stages of life or in fish that have been exposed to seawater. Nylund et al. (1999) reported a case of ISA in Atlantic salmon first feeding fry indicating that all stages are susceptible.

Horizontal transmission has been demonstrated using mucus, feces, urine, and blood in the laboratory (Totland et al. 1996; Nyland et al. 1994). Coprophagy and waterborne transmission have been identified as possible mechanisms for the spread of ISA virus. Experiments indicate that ectoparasites may play a role in transmission with the sea louse species *Lepeophtheirus salmonis* and *Caligus elongatus* being implicated as potential ISA virus vectors (Nylund et al. 1993). Vertical transmission has been suggested as a mode of virus transmission but remains unproven.

D. Disease Signs

Moribund fish are lethargic, anorexic, and swim high in the water column. They can have markedly pale gills, a slightly swollen abdomen, and exophthalmia and hemorrhaging of the eye. There may be ventral abdominal petechial hemorrhaging on the skin.

Internal gross signs can include swelling and reddening of the kidney, serosanguinous ascites, and petechial hemorrhaging throughout the peritoneal cavity. The liver is often enlarged and congested with a black or mottled appearance. Enlargement of the spleen has also been noted.

Anemia is highly variable but hematocrits of <10% are not uncommon in clinically affected fish.

Several pathological changes have been noted by histology in fish with ISA. The presence of renal interstitial hemorrhaging and tubular epithelial degeneration, necrosis, and casting within the posterior kidney have all been noted (Bouchard et al. 1999; Byrne et al. 1998). Liver sections show multifocal to confluent hemorrhagic hepatic necrosis, focal congestion, and dilatation of hepatic sinusoids (Speilberg et al. 1995; Evenson et al. 1991). Rupture of sinusoidal endothelium may also be observed.

E. Disease Diagnostic Procedures

1. Presumptive Diagnosis

In making a preliminary diagnosis of ISA, several factors such as the presence of gross clinical pathology, time since transfer to salt water, disease history of site, water temperature, and rate of mortality should be considered. Isolation of ISA virus can be accomplished with tissue from infected fish using standard cell culture techniques.

Kidney and spleen tissues (1cm³ sample size) are collected, homogenized, and diluted 1/10 in phosphate buffered saline. Tissue homogenates are further diluted 1/10 in Minimum Essential Medium (MEM) with Hank's salts, L-glutamine, and 2% fetal bovine serum (FBS). Samples are inoculated onto either the chinook salmon embryo (CHSE-214) or salmon head kidney (SHK) cell line at a volume of 0.1 mL/well and adsorbed for one hour. CHSE-214 cells are overlaid with 1 mL of MEM with Hank's, L-glutamine, 5% FBS, and gentamicin. SHK cells should be overlaid with Leibovitz's L-15, 5% FBS, and gentamicin. Inoculated cells are incubated at 16°C for 28 days. Cytopathic effect (CPE) seen in CHSE-214 cells is characterized by areas of refractile cells which can become confluent over time (Figure 1). In SHK cells, CPE is more diffuse, with refractile and necrotic cells present in the monolayer. CPE on either cell line can occur from 5 to 26 days (Bouchard et al. 1999).

2. Confirmatory Diagnosis

The routine method of confirmation of ISA virus is by RT-PCR (see Section 1, 2.2.8.1 ISA Appendix 1). Monoclonal antibodies have also been used to confirm cell culture supernatants using serum neutralization assays. Cell culture monolayers can be tested for ISA virus using the indirect fluorescent antibody technique (IFAT) using both monoclonal and polyclonal antibodies (Falk and Dannevig 1995).

F. Procedures for Detecting Subclinical Infections

IFAT and RT-PCR can be used in detecting sub-clinical infections but the detection limits of these assays have not been determined. Both tests are routinely used to determine clinical and sub-clinical infections in fish populations. Specific protocols are given in Section 1, 2.2.8.1 ISA Appendix 1 (ISAV RT-PCR) and Section 1, 2.2.8.1 ISA Appendix 2 (ISAV IFAT).

G. Procedures for Determining Prior Exposure to the Etiological Agent

Falk and Dannevig (1995b) found indirect evidence that fish exposed to ISA virus do possess neutralizing antibodies. Other more direct assays are not currently available.

H. Procedures of Transportation and Storage of Samples to Ensure Maximum Viability and Survival of the Etiological Agent

Direct tissue RT-PCR samples should be stored in RNA-later™ (Ambion, Inc.). Virus isolation samples should be stored in phosphate-buffered saline (pH 7.4). Tissue imprint slides for IFAT should be acetone-fixed as soon as possible. All samples should be transported on ice (4°C): virology samples should be processed and inoculated within 24 hours; RT-PCR and IFAT samples should be stored at -20°C if not run immediately.

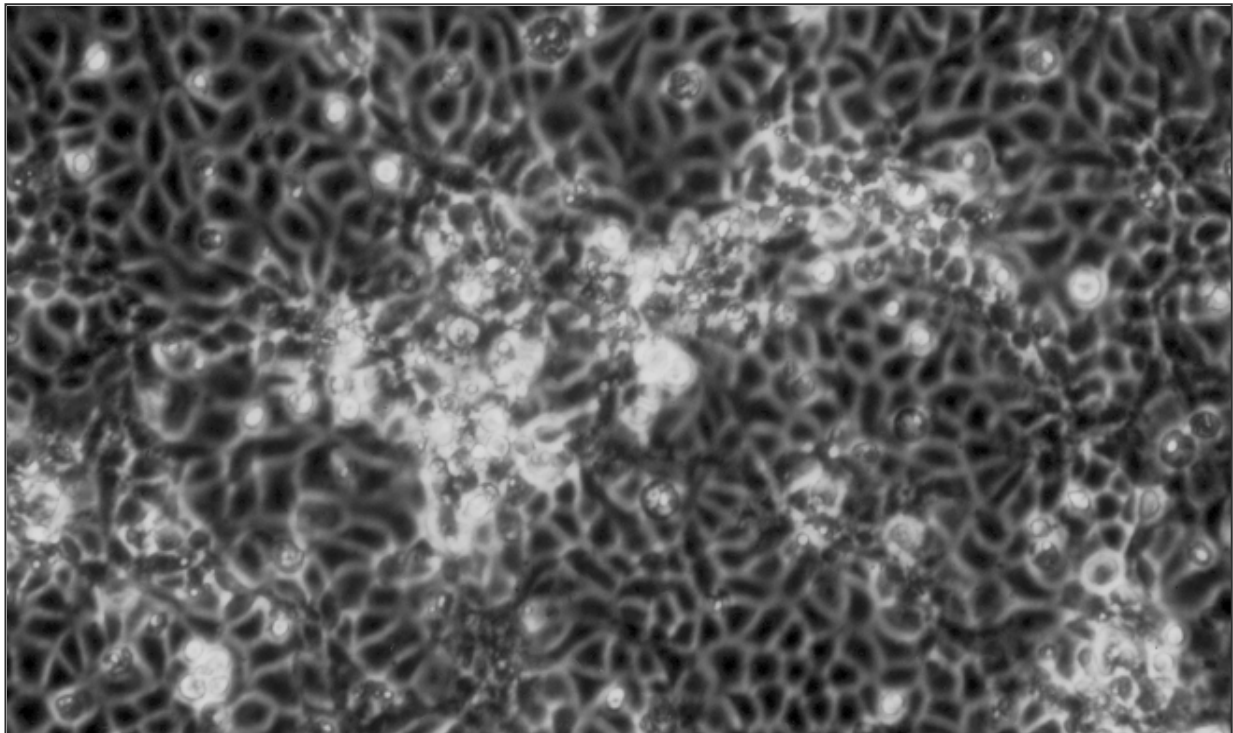


Figure 1. Cytopathic effect on CHSE-214 cells.

References

- Bouchard, D., W. Keleher, H. M. Opitz, S. Blake, K. C. Edwards, and B. L. Nicholson. 1999. Isolation of infectious salmon anemia virus (ISAV) from Atlantic salmon in New Brunswick, Canada. *Diseases of Aquatic Organisms* 35:131-137.
- Byrne, P. J., D. D. MacPhee, V. E. Ostland, G. Johnson, and H. W. Ferguson. 1998. Haemorrhagic kidney syndrome of Atlantic salmon, *Salmo salar* L. *Journal of Fish Diseases* 21:81-91.
- Eliassen, T. M., M. K. Frøystad, B. H. Dannevig, M. Jankowska, A. Brech, K. Falk, K. Romøren, and F. Gjøen. 2000. Initial events in infectious salmon anemia virus infection: evidence for the requirement of a low-pH step. *Journal of Virology* 74:218-227.
- Evenson, Ø., K. E. Thorud, and Y. A. Olsen. 1991. A morphological study of the gross and light microscopic lesions of infectious anaemia in Atlantic salmon (*Salmo salar*). *Research in Veterinary Science* 51:215-222.
- Falk, K., and B. H. Dannevig. 1995a. Demonstration of infectious salmon anemia (ISA) viral antigens in cell cultures and tissue sections. *Veterinary Research* 26:499-504.
- Falk, K., and B. H. Dannevig. 1995b. Demonstration of a protective immune response in infectious salmon anemia (ISA)-infected Atlantic salmon *Salmo salar*. *Diseases of Aquatic Organisms* 21:1-5.
- Nylund, A., T. Hovland, K. Hodneland, F. Nilsen, and P. Løvik. 1994. Mechanisms for transmission of infectious salmon anaemia (ISA). *Diseases of Aquatic Organisms* 19:95-100.
- Nylund, A., B. Krossøy, M. Devold, V. Aspehaug, N. O. Steine, and T. Hovland. 1999. Outbreak of ISA during first feeding of salmon fry (*Salmo salar*). *Bulletin of European Association of Fish Pathologists* 19(2):70-74.
- Nylund, A., C. Wallace, and T. Hovland. 1993. The Possible Role of *Lepeophtheirus salmonis* (Krøyer) in the Transmission of Infectious Salmon Anaemia. Pages 367-373 in G. Boxshall, and D. Defaye, editors. *Pathogens of Wild and Farmed Fish: Sea Lice*, Volume 28. Ellis Horwood Ltd., London.
- Speilberg, L., Ø. Evensen, and B. H. Dannevig. 1995. A sequential study of the light and electron microscopic liver lesions of infectious anemia in Atlantic salmon (*Salmo salar* L.). *Veterinary Pathology* 32:466-478.
- Totland, G. K., B. K. Hjeltnes, and P. R. Flood. 1996. Transmission of infectious salmon anaemia (ISA) through natural secretions and excretions from infected smolts of Atlantic salmon *Salmo salar* during their presymptomatic phase. *Diseases of Aquatic Organisms* 26:25-31.