

2.2.6 Viral Erythrocytic Necrosis

J. R. Winton¹ and P. K. Hershberger²

¹USGS Western Fisheries Research Center
6505 NE 65th Street
Seattle, WA 98115
and

²USGS Marrowstone Marine Field Station
616 Marrowstone Point Road
Nordland, WA 98358
206-526-6587 (JW) or 360-385-1007 ext. 225 (PH)
jwinton@usgs.gov; phershberger@usgs.gov

A. Name of Disease and Etiological Agent

Viral erythrocytic necrosis (VEN), originally termed piscine erythrocytic necrosis, is a condition that has been reported to affect the red blood cells (RBCs) of many species of marine and anadromous fishes in both the Atlantic and Pacific Oceans (Nicholson and Reno 1981; Smail 1982; Wolf 1988; Dannevig and Thorud 1999). Fish with VEN may develop a severe anemia that can reduce their stamina, predispose them to other infections or increase the impact of other stressors (MacMillan et al. 1980; Nicholson and Reno 1981; Meyers et al. 1986; Haney et al. 1992) resulting in population-scale impacts in susceptible species (Hershberger et al. 2009).

In spite of extensive efforts, the etiological agent of VEN has not been propagated in fish cell lines making its characterization difficult. However, transmission electron microscopy (TEM) of red blood cells from diseased fish convincingly demonstrates the presence of iridovirus-like particles that have been given the name erythrocytic necrosis virus (ENV). While the ENV virions in red blood cells of various species of fish from differing geographic locations may appear morphologically distinct (Smail 1982; Wolf 1988), at least one strain of ENV has now been partially sequenced, confirming it to be a member of the family *Iridoviridae* (Emmenegger et al. 2014; Purcell et al. 2016). However, the genetic relatedness of ENV strains from various fish hosts or geographic regions has not yet been investigated.

B. Known Geographical Range and Host Species of the Disease

1. Geographical Range

The geographic range of VEN is potentially global in the marine environment, although the majority of reports have involved marine or anadromous fish collected from coastal areas of the North Atlantic and North Pacific Oceans.

2. Host Species

The host range of ENV has been reported to extend through one or more species in families as diverse as hagfish, lampreys, sharks, skates and rays, and the bony fish (Wolf 1988). Among teleosts, virions or cytoplasmic inclusions typical of ENV have been observed in the RBCs of more than 20 marine or anadromous species (Dannevig and Thorud 1999). Experimental infections with ENV have demonstrated differences in host susceptibility (Evelyn and Traxler 1978; MacMillan and Mulcahy

1979; Reno et al. 1985). Although cross-species transmission has been performed experimentally, differences in virus strains or the effects of temperature on host susceptibility and disease progression have not been explored.

C. Epizootiology

An inability to isolate and propagate ENV using cell lines has resulted in a limited epizootiological understanding of the resulting disease. The causative virus is presumed to be maintained in populations of marine fish where infections are believed to be acquired via horizontal transmission from infected cohorts (Hershberger et al. 2009) and this route of transmission has been demonstrated experimentally (MacMillan and Mulcahy 1979; Nicholson and Reno 1981). However, inclusions and virus particles have been detected in juvenile salmonids reared exclusively in fresh water leading Rohovec and Amandi (1981) to speculate on the possibility of vertical transmission from infected anadromous adults.

Fish infected with ENV show variable levels of disease which may be related to route and intensity of exposure, stage of infection or relative host susceptibility. Laboratory infections of susceptible species have shown that the effects of VEN can persist for an extended period (Haney et al. 1992; Hershberger et al. 2006; Glenn et al. 2012) with significant deficits in physiological and hematological parameters that make them more susceptible to secondary infections or stressors (MacMillan et al. 1980; Nicholson and Reno 1981; Haney et al. 1992). In natural epizootics associated with significant mortality, VEN is often seen in conjunction with other infections (Hershberger et al. 2006) or in association with severe stressors such as low dissolved oxygen and low salinity (Meyers et al. 1986). A multi-year field study revealed that VEN was associated with a population-level loss in Pacific herring and suggested the disease can be an important component of natural mortality in some species of marine fish (Hershberger et al. 2009).

D. Disease Signs

The most common and consistent disease sign among the species affected is anemia, which can be observed externally as pale gills (Figure 1) and internally as a general pallor of visceral organs. In severe cases, hematocrits may be as low as 2 to 10% leading to coagulopathy, and stained blood smears reveal severe blood dyscrasias characterized by erythroblastosis, leucocytosis, erythroid cell destruction and cytoplasmic inclusions of differing morphology in erythrocytes and erythroblasts (Reno et al. 1985; MacMillan et al. 1989). The percentage of erythrocytes demonstrating inclusions can range from less than 1% in normal-appearing fish to 100% in fish experiencing severe anemia. Fish with clinical VEN also show greatly reduced stamina and losses are often associated with secondary infections (Hershberger et al. 2006) or the inability of ENV-infected fish to deal with stressors (Meyers et al. 1986).

E. Disease Diagnostic Procedures

1. Presumptive Diagnosis

Because ENV has proven refractory to isolation using any of the numerous fish cell lines tested, the presumptive diagnosis of VEN depends on observation of inclusion bodies in the cytoplasm of infected erythrocytes. Blood smears are made, air dried, fixed for five minutes in absolute methanol, stained with Giemsa, Wright, or other standard blood stains and examined by light microscopy for the presence of cytoplasmic inclusion bodies that are typically paranuclear, single, and range in size from 1 to 4 μm in diameter (Figure 2).

Although best known as a stain for observation of inclusions in the RBCs of salmon with erythrocytic inclusion body syndrome (EIBS), pinacyanol chloride (Leek 1987) has also been used to stain blood smears for VEN diagnosis. If blood is not available for examination, stained smears prepared from blood-rich tissues such as kidney or spleen can be used.

Methanol/ethanol (1:1) fixed smears can also be rehydrated in a graded ethanol series (100%, 70%, and 50%), stained with 0.1% aqueous acridine orange and washed in phosphate buffered saline to

aid in differentiating inclusions of EIBS from those of VEN. Inclusions of VEN stain green; those of EIBS stain orange.

2. Confirmatory Diagnosis

A confirmed diagnosis of VEN depends on transmission electron microscopy (TEM) to observe iridovirus-like particles within the cytoplasm of erythrocytes using methods described by Glenn et al. (2012). In thin sections, the classically described virion outer coat is typically hexagonal in outline and there is usually a closely apposed inner coat that surrounds a centrally-located circular nucleoid (Figure 3). The reported diameters of the ENV virions in teleosts range from 145 nm in the Atlantic herring to 330 nm in the Atlantic cod (Walker and Sherburne 1977; Nicholson and Reno 1981).

3. Molecular Assays

Both standard (Emmenegger et al. 2014) and real-time (Purcell et al. 2016) PCR assays have been developed using genomic sequences of a strain of ENV from Pacific herring in Puget Sound, Washington. While highly sensitive and specific for this strain of the virus, the assays have not been tested using samples from VEN-affected fish in other regions of the world.

F. Procedures for Detecting Subclinical Infections

Two real-time PCR assays (Purcell et al. 2016) have been evaluated for diagnostic sensitivity and specificity using tissues of infected herring from laboratory challenges. The assays demonstrated similar performance as light microscopy of stained blood smears. However, the qPCR assays could also detect viral DNA early in infection prior to the formation of inclusion bodies.

G. Procedures for Determining Prior Exposure to the Etiological Agent

No procedures have been reported.

H. Procedures for Transportation and Storage of Samples to Ensure Maximum Viability and Survival of the Etiological Agent

It is best to make blood smears on site and fix them with absolute methanol before transporting to a laboratory. If blood is to be examined by transmission electron microscopy, 10 to 20 units of heparin must be added per mL of blood and the samples should be transported on ice and placed in Hawke's fixative within 48 hours of collection (Rohovec and Amandi 1981). For molecular assays, blood-containing tissues or heparinized blood can be shipped on ice if they will be processed within 24 hours. Otherwise, they can be frozen or placed in ethanol for transportation and storage.

I. Procedures for Enumeration of ENV

Enumeration of ENV in erythrocytes of fish relies on TEM examination of fixed blood or blood-containing tissues using methods provided by Glenn et al. (2012) who reported that inclusion numbers do not agree well with estimates of virus load based upon TEM observation of blood or hematopoietic tissues. Estimates of virus load can also be determined by the real-time PCR assays of Purcell et al. (2016).

J. Procedures for Determination of Disease-free Status

None are available.



Figure 1. Gills of Pacific herring experimentally infected with ENV (top); note the pale color due to the severe anemia. Bottom fish is an uninfected control. Photo by Paul Hershberger.

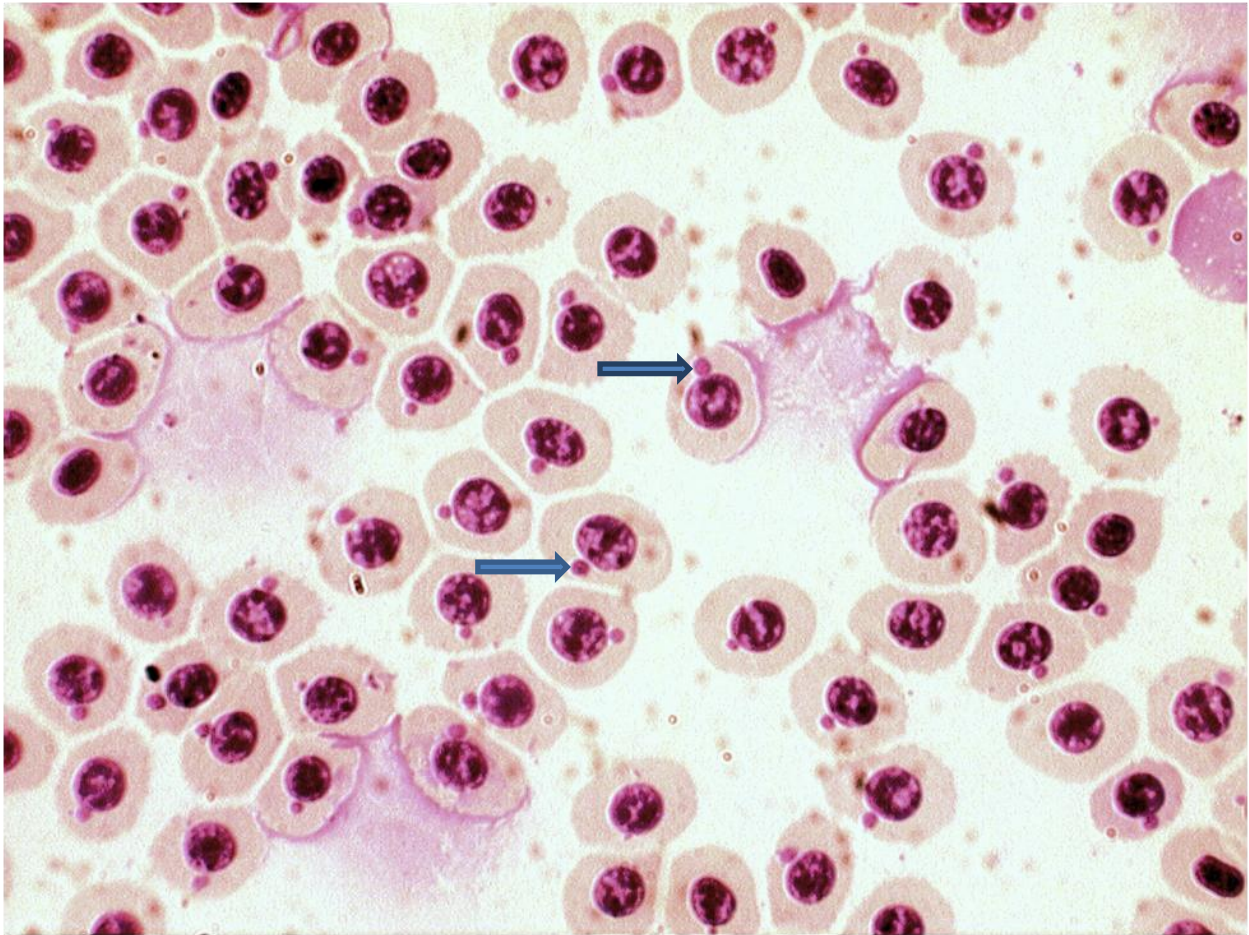


Figure 2. Red blood cells of Pacific herring experimentally infected with ENV. Note the presence of inclusion bodies (arrows) in a high percentage of erythrocytes. Photo by Paul Hershberger

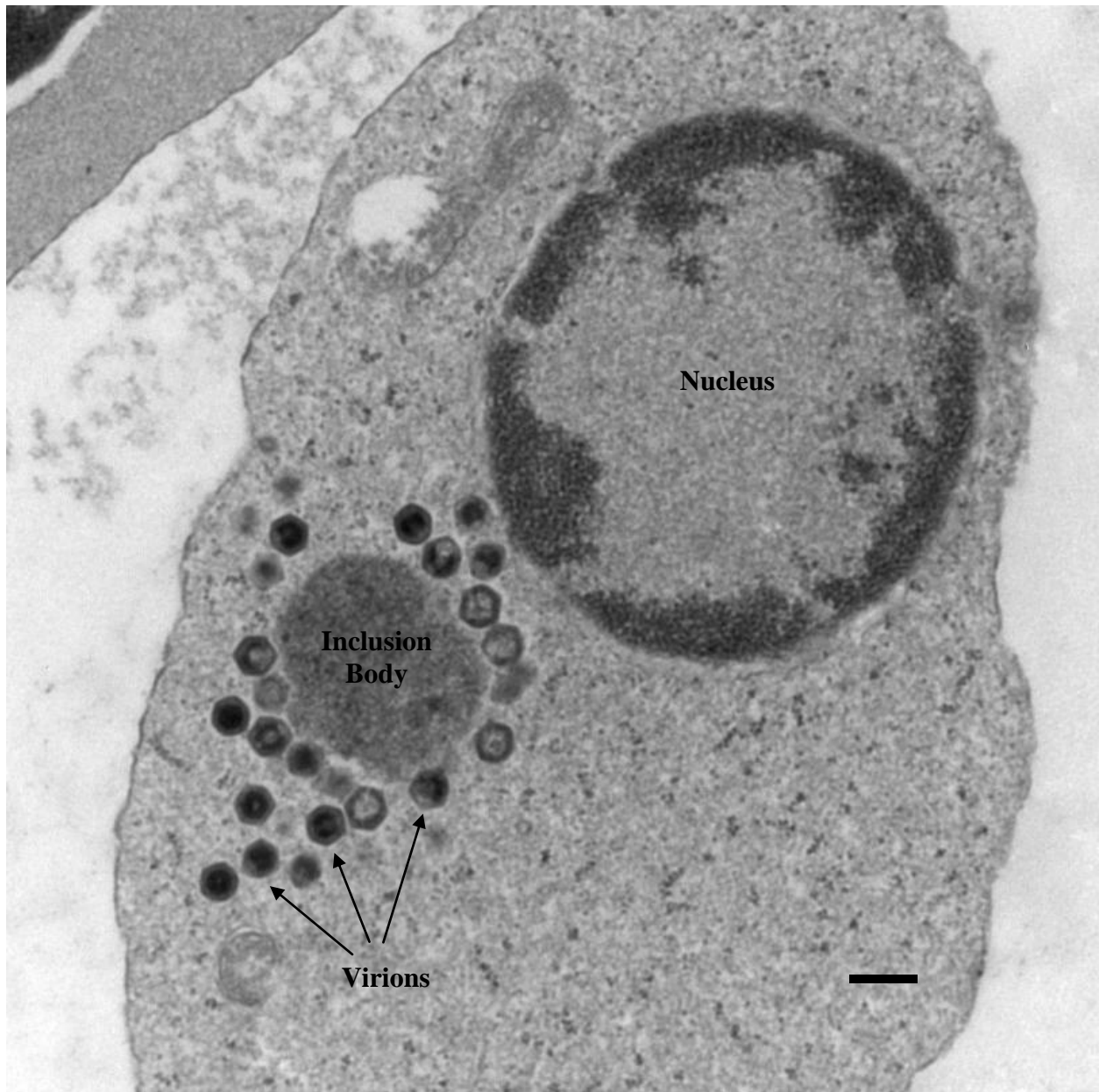


Figure 3. Ultrathin section of a red blood cell viewed by transmission electron microscopy. Note the electron-dense core of the icosahedral virions typical of iridoviruses. Bar equals 300nm. Photo by Jim Winton.

References

- Dannevig, B. H., and K. E. Thorud. 1999. Other viral diseases and agents of cold-water fish: infectious salmon anaemia, pancreas disease and viral erythrocytic necrosis. Pages 164-175 in P. T. K. Woo and D. W. Bruno, editors. Fish diseases and disorders, volume 3 (eds). CABI Publishing, New York.
- Emmenegger, E.J., J.A. Glenn, J.R. Winton, W.N. Batts, J.L. Gregg, and P.K. Hershberger. 2014. Molecular identification of erythrocytic necrosis virus (ENV) from the blood of Pacific herring (*Clupea pallasii*). Veterinary Microbiology 174:16-26.
- Evelyn, T. P. T., and G. S. Traxler. 1978. Viral erythrocytic necrosis: natural occurrence in Pacific salmon and experimental transmission. Journal of the Fisheries Research Board of Canada 35:903-907.
- Glenn, J. A., E. J. Emmenegger, C. A. Grady, S. R. Roon, J. L. Gregg, C. M. Conway, J. R. Winton and P. K. Hershberger. 2012. Kinetics of viral load and erythrocytic inclusion body formation in Pacific herring artificially infected with erythrocytic necrosis virus. Journal of Aquatic Animal Health 24:195-200.
- Haney, D. C., D. A. Hursh, M. C. Mix, and J. R. Winton. 1992. Physiological and hematological changes in chum salmon artificially infected with erythrocytic necrosis virus. Journal of Aquatic Animal Health 4:48-57.
- Hershberger, P., A. Hart, J. Gregg, N. Elder, and J. Winton. 2006. Dynamics of viral hemorrhagic septicemia, viral erythrocytic necrosis and ichthyophoniasis in confined Pacific herring *Clupea pallasii*. Diseases of Aquatic Organisms 70:201-208.
- Hershberger, P. K., N. E. Elder, C. A. Grady, J. L. Gregg, C. A. Pacheco, C. Greene, C. Rice, and T. R. Meyers. 2009. Prevalence of viral erythrocytic necrosis in Pacific herring and epizootics in Skagit Bay, Puget Sound, Washington. Journal of Aquatic Animal Health 21:1-7.
- Leek, S. L. 1987. Viral erythrocytic inclusion body syndrome (EIBS) occurring in juvenile spring Chinook salmon (*Oncorhynchus tshawytscha*) reared in fresh water. Canadian Journal of Fisheries and Aquatic Sciences 44:685-686.
- MacMillan, J. R., and D. Mulcahy. 1979. Artificial transmission to and susceptibility of Puget Sound fish to viral erythrocytic necrosis (VEN). Journal of the Fisheries Research Board of Canada 36:1097-1101.
- MacMillan, J. R., D. Mulcahy, and M. Landolt. 1980. Viral erythrocytic necrosis: some physiological consequences of infection in chum salmon (*Oncorhynchus keta*). Canadian Journal of Fisheries and Aquatic Sciences 37:799-804.
- MacMillan, J. R., D. Mulcahy, and M. Landolt. 1989. Cytopathology and coagulopathy associated with viral erythrocytic necrosis in chum salmon. Journal of Aquatic Animal Health 1:255-262.
- Meyers, T. R., A. K. Hauck, W. D. Blankenbeckler, and T. Minicucci. 1986. First report of viral erythrocytic necrosis in Alaska, USA, associated with epizootic mortality in Pacific herring, *Clupea harengus pallasii* (Valenciennes). Journal of Fish Diseases 9:479-491.
- Nicholson, B. L., and P. W. Reno. 1981. Viral erythrocytic necrosis (VEN) in marine fishes. Fish Pathology 15:129-133.
- Purcell, M.K., S. Pearman-Gillman, R.L. Thompson, J.L. Gregg, L.M. Hart, J.R. Winton, E.J. Emmenegger, and P.K. Hershberger. 2016. Identification of the major capsid protein of erythrocytic necrosis virus (ENV) and development of real-time PCR assays for quantification of ENV DNA. Journal of

2.2.7 Viral Erythrocytic Necrosis - 8

Veterinary Diagnostic Investigation. 28:382-391.

Reno, P. W., D. V. Serreze, S. K. Hellyer, and B. L. Nicholson. 1985. Hematological and physiological effects of viral erythrocytic necrosis (VEN) in Atlantic cod and herring. *Fish Pathology* 20:353-360.

Rohovec, J. S., and A. Amandi. 1981. Incidence of viral erythrocytic necrosis among hatchery reared salmonids in Oregon. *Fish Pathology* 15:135-141.

Smail, D. A. 1982. Viral erythrocytic necrosis in fish: a review. *Proceedings of the Royal Society of Edinburgh* 81B: 169-176.

Walker, R., and S. W. Sherburne. 1977. Piscine erythrocytic necrosis virus in Atlantic cod *Gadus morhua*, and other fish: ultrastructure and distribution. *Journal of the Fisheries Research Board of Canada* 34:1188-1195.

Wolf, K. 1988. Viral erythrocytic necrosis. Pages 389-398 *in* *Fish Viruses and Fish Viral Diseases*. Cornell University Press. Ithaca, New York.